

# Looped and Tortuous Ulnar Artery – An Erratic Unilateral Vascular Presentation in the Proximal Forearm

VINCENT RODRIGUES<sup>1</sup>, MOHANDAS KG RAO<sup>2</sup>, SHIVANANDA NAYAK<sup>3</sup>, NAVEEN KUMAR<sup>4</sup>

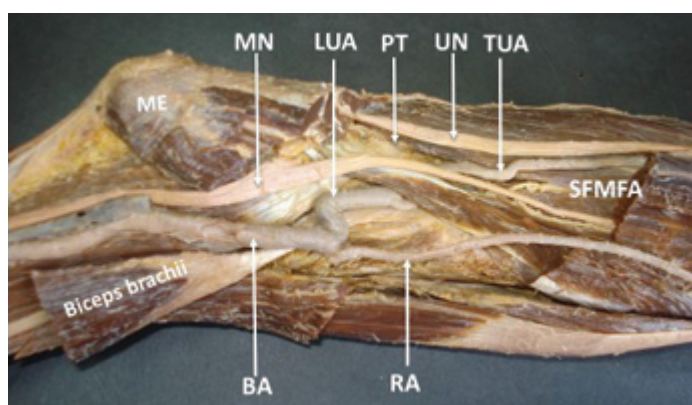
## ABSTRACT

Precise and detailed knowledge of possible anatomical variations of the arterial pattern in the upper extremity is vital during reparative surgery in this region. Scientific literatures witnessed several reports on variant origin and branching pattern of ulnar artery. But report on looped and tortuous ulnar artery is lacking in the literature. We report here a unique case of ulnar artery having double loop at its commencement giving it an appearance of sigmoid shape and its undue tortuous course in the forearm. Such an unusual and unpredictable variation of ulnar artery is vulnerable for life threatening hemorrhage during clinical approaches. It could also lead to misinterpretation of CT scans as presence of tumours. Awareness on such exceptional anatomical discrepancy of ulnar artery is important to clinicians, neuroradiologists and radiologists in general.

**Keywords:** Anatomical variations, Arterial variation, Sigmoid shape

## CASE REPORT

During routine cadaveric dissection of cubital fossa, we noticed normal termination of brachial artery into radial and ulnar arteries. However, on tracing ulnar artery, we observed abrupt looping pattern at its commencement. Due to presence of loops, the ulnar artery appeared to be sigmoid shaped and kinked at two points at the site of its origin. The proximal bend was U-shaped with the concavity upwards, while distal bend was inverted U-shaped with the concavity downwards. Further probe into its course on the forearm revealed normal deeper course beneath the superficial flexor muscles of forearm with remarkable tortuous course at proximal part of the forearm [Table/Fig-1]. Nevertheless, its distal course and entire branching pattern was unremarkable. The course of ulnar nerve remained normal as expected with respect to ulnar artery. No other vascular abnormalities were found in the affected limb and this unilateral arterial variation was found on the right upper limb of an adult human corpse aged about 60 years.



**[Table/Fig-1]:** Dissection of cubital fossa showing the termination of Brachial Artery (BA) into Radial Artery (RA) and Looped Ulnar Artery (LUA). The Tortuous Course of Ulnar Artery (TUA) is also seen at proximal forearm. UN- ulnar nerve, MN- median nerve, ME- Medial epicondyle with common origin of superficial flexor muscles of forearm (SFMFA), PT – pronator teres.

## DISCUSSION

Variant vascular patterns in the upper extremity have gained much clinical attention and have been subject of anatomical studies because of their higher prevalence. Though there is sufficient number of reports on clinically significant vascular variations in the scientific literature, an unusual appearance of ulnar artery with the

presentation of abrupt looping and tortuous course at proximal forearm is hardly ever reported.

Ulnar artery is the largest terminal branch of brachial artery given off in the cubital fossa. On its further course, it lies beneath the superficial flexor muscles of forearm in the proximal third of forearm and in the distal two third of forearm it descends vertically downwards with the sub fascial course [1]. Throughout its course in the forearm it doesn't present any looping or tortuous pattern.

Two major clinically significant anatomical variations of ulnar artery as reported by Rodriguez et al., in their extensive study of variations of arterial pattern in the upper limb are: (a) superficial brachioulnar artery in which high origin of ulnar artery either from axillary or from upper segment of brachial artery followed by its subsequent superficial course. In an estimation, this prevalence accounts for 4.2%; and (b) brachioulnar artery in which high origin of ulnar artery was associated with normal course along the forearm and hand. This variant form of the ulnar artery accounts for 0.26% of incidence [2]. Looped and tortuous course of ulnar artery is rarest of its anatomical variation. Tortuosity of ulnar artery at distal forearm and hand has been reported [3-5].

In the present case, a peculiar morphology of ulnar artery with the abrupt loops at its site of origin and tortuous course in proximal forearm without any other associated malformations or lesion of neighboring structures were seen. It was believed previously that the individuals with a family history of tortuous blood vessels are vulnerable to be affected by aneurysms and blood clots due to tortuous arteries [6,7]. Mahajan et al., however deny such assumptions while reporting a case of distal tortuous ulnar artery without any symptoms of aneurysms [5].

Exact cause for the unusual tortuosity of arteries is not clear. However, paucities in the normal ongoing repair of arteries is said to be a probable cause for tortuosity. This altered mechanism would also result in tendency to pool and clot the blood at the bends of the loops of the arterial lane. Abnormal tortuosity or looping of artery may also be due to genetic or other ill conditions as in atherosclerosis, hypertension and also disease in which thickening of the arteries occur [8,9].

Uncommon looping and tortuous arteries in the upper limb not only result in dangerous and problematic surgical approaches but also mislead the clinician in the interpretation of CT scans as a solid masses or tumours [5]. Further, looped or tortuous vessels are

vulnerable to get punctured or perforated easily in interventional procedures.

Ulnar artery could also be a vessel of choice for cardiac catheterization, provided special care is taken to avoid complications during puncture [10]. This attempt is contra-indicatory in the present variant form of ulnar artery due to presence of multiple bends. In recent years, ulnar artery is gaining much importance for the percutaneous coronary intervention when the radial approach seems to be unsuitable for various reasons [11]. The ulnar artery is also preferred by the neuroradiologists for the cerebral angiography in cases where the trans-radial approach is not advisable [12]. In these instances, ascertaining normal anatomy of the ulnar artery is imperative to concerned clinicians beforehand to avoid any iatrogenic injuries to the artery.

## CONCLUSION

Unusual looped pattern of ulnar artery with the tortuous course could be considered as a dangerous arterial malformation that would lead to intra-arterial injections instead of vein in the cubital fossa and many other complications at times. Abrupt looping pattern and tortuous course of ulnar artery as reported in the present case would also interfere with the ulnar artery catheterization as done in the rare case of failed attempt to cannulate radial artery. Therefore, awareness on such rare anatomical discrepancy of ulnar artery is important to clinicians, neuroradiologists and radiologists in general.

## REFERENCES

- [1] Standring S, Borley NR, Collins P, Crossman AR, Gatzoulis MA, Healy JC, et al. Gray's Anatomy: The anatomical basis of clinical practice. forearm, wrist and hand. 40<sup>th</sup> edition. London: Churchill Livingstone, 2008; Pp. 852, 893-94.
- [2] Rodriguez-Niedenfuhr, Vasquez T, Nearn L, Ferreira B, Parkin I, Sannudo JR. Variations of the arterial pattern in the upper limb revisited: a morphological and statistical study, with a review of the literature. *J Anat.* 2001;199:547-66.
- [3] Emel E, Guzey FK, Alatas I. Guyon's canal syndrome due to tortuous ulnar artery: a case report. *Turk Neurosurg.* 2003;13:107-10.
- [4] Jose RM, Bragg T, Srivastava S. Ulnar nerve compression in Guyon's canal in the presence of a tortuous ulnar artery. *J Hand Surg Br.* 2006;31(2):200-02.
- [5] Mahajan R, Raheja S, Tuli A, Singh S, Agarwal S. Tortuous ulnar artery and Gantzer's muscle: A rare presentation with clinical implications. *IAIM.* 2015;2(7):141-46.
- [6] Dodds SR. Aneurysmal arterial disease. 2001. Available at [http://www.ehow.com/about\\_6633259\\_tortuous-artery\\_.html](http://www.ehow.com/about_6633259_tortuous-artery_.html)
- [7] Yoshii S, Ikeda K, Murakami H. Ulnar nerve compression secondary to ulnar artery true aneurysm at Guyon's canal. *J Neurosurg Sci.* 1999;43:295-97.
- [8] Taarnhoj NCB, Munch IC, Sander B, Kessel L, Hougaard JL, Kyvik K. Straight versus tortuous retinal arteries in relation to blood pressure and genetics. *British Journal of Ophthalmology.* 2008;92:1055-60.
- [9] Bhat V, Muzrakchi AA. Meandering Vessels: A sign of arterial tortuosity on plain chest radiography. *Heart Views.* 2008;9:24-6.
- [10] Valdesuso R, Gimeno JR, Lacunza FJ, Rodriguez JA, Toruncha A, de Lara JG, et al. CRT-177 Ulnar artery, is it as safe as the radial for cardiac catheterization? *J Am Coll Cardiol Interv.* 2014;7(2\_S):S32-S32.
- [11] Valsecchi O, Vassileva A, Musumeci G, Rossini R, Tespili M, Guagliumi G, et al. Failure of trans-radial approach during coronary interventions: Anatomic considerations. *Cathet Cardiovasc Interv.* 2006;67:870-78.
- [12] Layton KF, Kallmes DF, Kaufmann TJ. Use of the ulnar artery as an alternative access site for cerebral angiography. *AJNR Am J Neuroradiology.* 2006;27(10):2073-74.

### PARTICULARS OF CONTRIBUTORS:

1. Professor, Department of Preclinical Sciences, Faculty of Medical Sciences, University of the West Indies, St. Augustine, Trinidad and Tobago, West Indies.
2. Professor, Department of Anatomy, Melaka Manipal Medical College, Manipal Campus, Manipal University, Manipal, Karnataka, India.
3. Professor, Department of Preclinical Sciences, Faculty of Medical Sciences, University of the West Indies, St. Augustine, Trinidad and Tobago, West Indies.
4. Assistant Professor, Department of Anatomy, Melaka Manipal Medical College, Manipal Campus. Manipal University, Manipal, Karnataka, India.

### NAME, ADDRESS, E-MAIL ID OF THE CORRESPONDING AUTHOR:

Dr. Naveen Kumar,  
Professor, Department of Anatomy, Melaka Manipal Medical College, Manipal Campus,  
Manipal University, Manipal, Karnataka-576104, India.  
E-mail: naveentonse@gmail.com

Date of Submission: **Apr 16, 2016**  
Date of Peer Review: **May 02, 2016**  
Date of Acceptance: **May 06, 2016**  
Date of Publishing: **Jun 01, 2016**

FINANCIAL OR OTHER COMPETING INTERESTS: None.